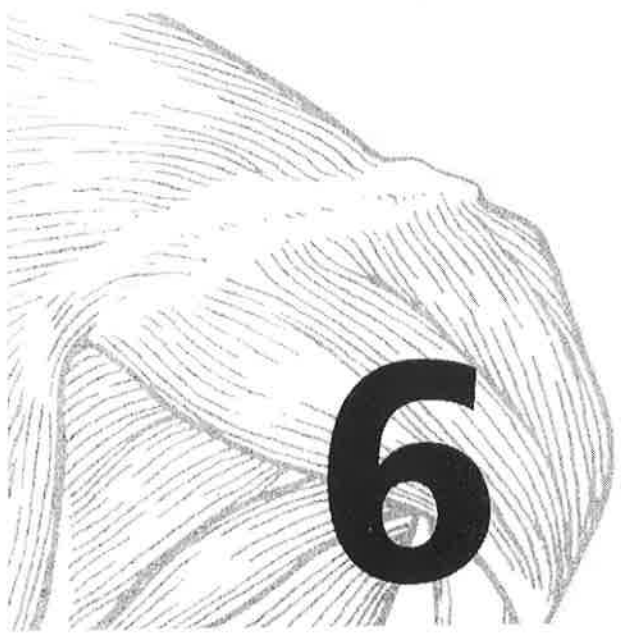

THE MUSCULAR SYSTEM

Muscles, the specialized tissues that facilitate body movement, make up about 40% of body weight. Most body muscle is the voluntary type, called skeletal muscle because it is attached to the bony skeleton. Skeletal muscle contributes to body contours and shape, and it composes the organ system called the muscular system. These muscles allow you to grin, frown, run, swim, shake hands, swing a hammer, and to otherwise manipulate your environment. The balance of body muscle is smooth and cardiac muscles, which form the bulk of the walls of hollow organs and the heart. Smooth and cardiac muscles are involved in the transport of materials within the body.

Study activities in this chapter deal with microscopic and gross structure of muscle, identification of voluntary muscles, body movements, and important understandings of muscle physiology.

OVERVIEW OF MUSCLE TISSUES

1. Nine characteristics of muscle tissue are listed below and on page 104. Identify the muscle tissue type described by choosing the correct response(s) from the key choices. Enter the appropriate term(s) or letter(s) of the key choice in the answer blank.

Key Choices

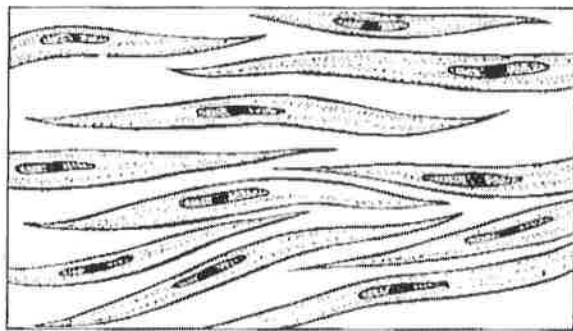
- A. Cardiac B. Smooth C. Skeletal

- _____ 1. Involuntary
- _____ 2. Banded appearance
- _____ 3. Longitudinally and circularly arranged layers
- _____ 4. Dense connective tissue packaging
- _____ 5. Figure-8 packaging of the cells
- _____ 6. Coordinated activity to act as a pump

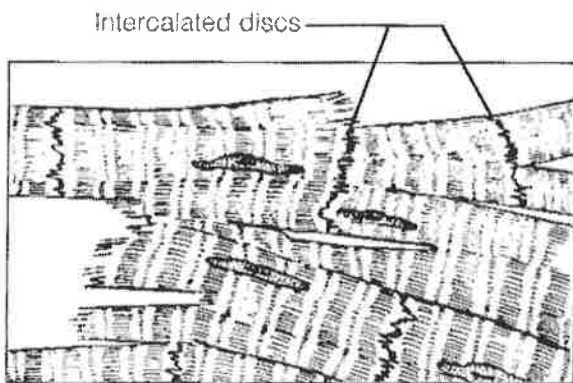


- _____ 7. Moves bones and the facial skin
 _____ 8. Referred to as the muscular system
 _____ 9. Voluntary

2. Identify the type of muscle in each of the illustrations in Figure 6-1. Color the diagrams as you wish.



A _____



B _____

Figure 6-1

3. Regarding the functions of muscle tissues, circle the term in each of the groupings that does not belong with the other terms.

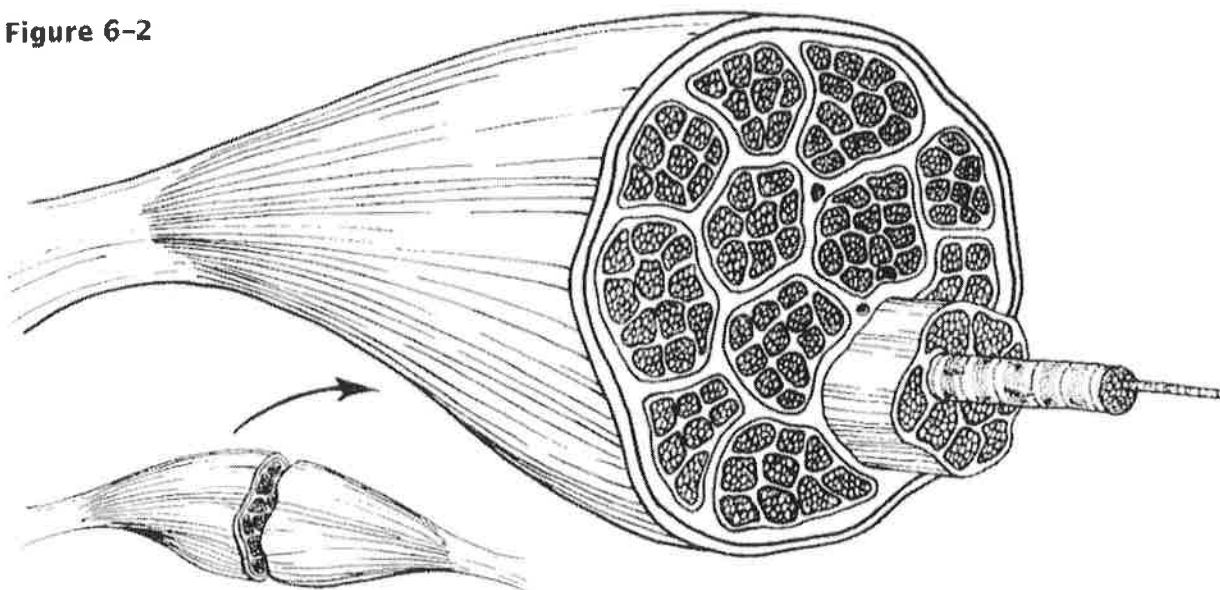
- | | | | |
|-----------------------|------------------------|-----------------|-----------------------------|
| 1. Urine | Foodstuffs | Bones | Smooth muscle |
| 2. Heart | Cardiac muscle | Blood pump | Promotes labor during birth |
| 3. Excitability | Response to a stimulus | Contractility | Action potential |
| 4. Ability to shorten | Contractility | Pulls on bones | Stretchability |
| 5. Maintains posture | Movement | Promotes growth | Generates heat |

MICROSCOPIC ANATOMY OF SKELETAL MUSCLE

4. First, identify the structures in Column B by matching them with the descriptions in Column A. Enter the correct letters (or terms if desired) in the answer blanks. Then, select a different color for each of the terms in Column B that has a color-coding circle and color in the structures on Figure 6-2.

Column A	Column B
_____ 1. Connective tissue surrounding a fascicle	A. Endomysium <input type="radio"/>
_____ 2. Connective tissue ensheathing the entire muscle	B. Epimysium <input type="radio"/>
_____ 3. Contractile unit of muscle	C. Fascicle <input type="radio"/>
_____ 4. A muscle cell	D. Fiber <input type="radio"/>
_____ 5. Thin connective tissue investing each muscle cell	E. Myofilament <input type="radio"/>
_____ 6. Plasma membrane of the muscle cell	F. Myofibril <input type="radio"/>
_____ 7. A long, filamentous organelle found within muscle cells that has a banded appearance	G. Perimysium <input type="radio"/>
_____ 8. Actin- or myosin-containing structure	H. Sarcolemma <input type="radio"/>
_____ 9. Cordlike extension of connective tissue beyond the muscle, serving to attach it to the bone	I. Sarcomere <input type="radio"/>
_____ 10. A discrete bundle of muscle cells	J. Sarcoplasm <input type="radio"/>
	K. Tendon <input type="radio"/>

Figure 6-2



5. Figure 6-3 is a diagrammatic representation of a small portion of a relaxed muscle cell (bracket indicates the portion enlarged). First, select different colors for the structures listed below. Use them to color the coding circles and corresponding structures on Figure 6-3. Then bracket and label an A band, an I band, and a sarcomere. When you have finished, draw a contracted sarcomere in the space beneath the figure and label the same structures, as well as the light and dark bands.

- Myosin Actin filaments Z disc

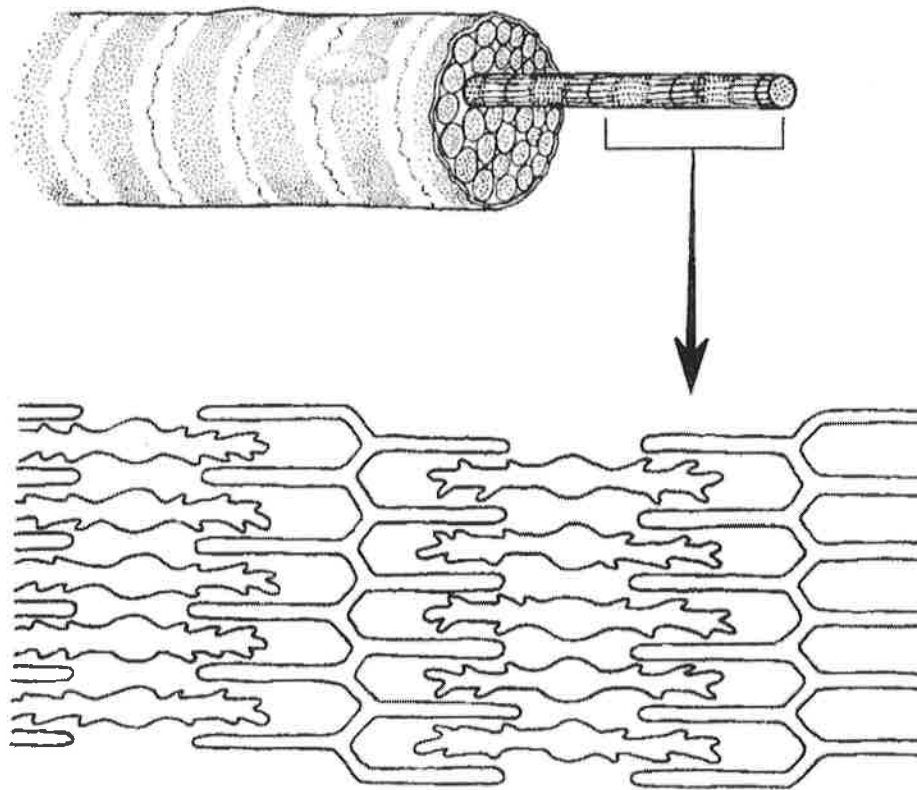


Figure 6-3

1. Looking at your diagram of a contracted sarcomere from a slightly different angle, which region of the sarcomere shortens during contraction—the dark band, the light band, or both?

15. Complete the following statements. Insert your answers in the answer blanks.

- _____ 1. Standing on your toes as in ballet is (1) of the foot. Walking on your heels is (2).
- _____ 2. _____
- _____ 3. Winding up for a pitch (as in baseball) can properly be called (3). To keep your seat when riding a horse, the tendency is to (4) your thighs.
- _____ 4. _____
- _____ 5. In running, the action at the hip joint is (5) in reference to the leg moving forward and (6) in reference to the leg in the posterior position. When kicking a football, the action at the knee is (7). In climbing stairs, the hip and knee of the forward leg are both (8). You have just touched your chin to your chest; this is (9) of the neck.
- _____ 6. _____
- _____ 7. _____
- _____ 8. Using a screwdriver with a straight arm requires (10) of the arm. Consider all the movements of which the arm is capable.
- _____ 9. One often used for strengthening all the upper arm and shoulder muscles is (11).
- _____ 10. _____
- _____ 11. Moving the head to signify "no" is (12). Action that moves the distal end of the radius across the ulna is (13). Raising the arms laterally away from the body is called (14) of the arms.
- _____ 12. _____
- _____ 13. _____
- _____ 14. _____

16. The terms provided in the key are often used to describe the manner in which muscles interact with other muscles. Select the key terms that apply to the following definitions and insert the correct letter or term in the answer blanks.

Key Choices

- A. Antagonist B. Fixator C. Prime mover D. Synergist

- _____ 1. Agonist
- _____ 2. Postural muscles for the most part
- _____ 3. Stabilizes a joint so that the prime mover can act at more distal joints
- _____ 4. Performs the same movement as the prime mover
- _____ 5. Reverses and/or opposes the action of a prime mover
- _____ 6. Immobilizes the origin of a prime mover

17. Several criteria are applied to the naming of muscles. These are provided in Column B. Identify which criteria pertain to the muscles listed in Column A and enter the correct letter(s) in the answer blank.

Column A	Column B
_____ 1. Gluteus maximus	A. Action of the muscle
_____ 2. Adductor magnus	B. Shape of the muscle
_____ 3. Biceps femoris	C. Location of the muscle's origin and/or insertion
_____ 4. Transversus abdominis	D. Number of origins
_____ 5. Extensor carpi ulnaris	E. Location of muscle relative to a bone or body region
_____ 6. Trapezius	F. Direction in which the muscle fibers run relative to some imaginary line
_____ 7. Rectus femoris	G. Relative size of the muscle
_____ 8. External oblique	

GROSS ANATOMY OF THE SKELETAL MUSCLES

Muscles of the Head

18. Identify the major muscles described in Column A by choosing a response from Column B. Enter the correct letter in the answer blank. Select a different color for each muscle described and color in the coding circle and corresponding muscle on Figure 6-6. *— on pg. 113 in back of packet*

Column A	Column B
<input type="radio"/> _____ 1. Used in smiling	A. Buccinator
<input type="radio"/> _____ 2. Used to suck in your cheeks	B. Frontalis
<input type="radio"/> _____ 3. Used in winking	C. Masseter
<input type="radio"/> _____ 4. Used to form the horizontal frown crease on the forehead	D. Orbicularis oculi
<input type="radio"/> _____ 5. The "kissing" muscle	E. Orbicularis oris
<input type="radio"/> _____ 6. Prime mover of jaw closure	F. Sternocleidomastoid
<input type="radio"/> _____ 7. Synergist muscle for jaw closure	G. Temporalis
<input type="radio"/> _____ 8. Prime mover of head flexion; a two-headed muscle	H. Trapezius
	I. Zygomaticus

Muscles of the Trunk

19. Identify the anterior trunk muscles described in Column A by choosing a response from Column B. Enter the correct letter in the answer blank. Then, for each muscle description that has a color-coding circle, select a different color to color the coding circle and corresponding muscle on Figure 6-7. — pg 115

Column A

- _____ 1. The name means "straight muscle of the abdomen"
- _____ 2. Prime mover for shoulder flexion and adduction
- _____ 3. Prime mover for shoulder abduction
- _____ 4. Part of the abdominal girdle; forms the external lateral walls of the abdomen
- _____ 5. Acting alone, each muscle of this pair turns the head toward the opposite shoulder
- _____ 6. and 7. Besides the two abdominal muscles (pairs) named above, two muscle pairs that help form the natural abdominal girdle
- _____ 8. Deep muscles of the thorax that promote the inspiratory phase of breathing
- _____ 9. An unpaired muscle that acts with the muscles named immediately above to accomplish inspiration

Column B

- A. Deltoid
- B. Diaphragm
- C. External intercostal
- D. External oblique
- E. Internal intercostal
- F. Internal oblique
- G. Latissimus dorsi
- H. Pectoralis major
- I. Rectus abdominis
- J. Sternocleidomastoid
- K. Transversus abdominis

20. Identify the posterior trunk muscles described in Column A by choosing a response from Column B. Enter the correct letter in the answer blank. Select a different color for each muscle description with a coding circle and color the coding circles and corresponding muscles on Figure 6-8.

pg 117

Column A

Column B

- _____ 1. Muscle that allows you to shrug your shoulders or extend your head
- _____ 2. Muscle that adducts the shoulder and causes extension of the shoulder joint
- _____ 3. Shoulder muscle that is the antagonist of the muscle just described
- _____ 4. Prime mover of back extension; a deep composite muscle consisting of three columns
- _____ 5. Large paired superficial muscle of the lower back
- _____ 6. Fleshy muscle forming part of the posterior abdominal wall that helps maintain upright posture

- A. Deltoid
- B. Erector spinae
- C. External oblique
- D. Gluteus maximus
- E. Latissimus dorsi
- F. Quadratus lumborum
- G. Trapezius

Muscles of the Hip, Thigh, and Leg

21. Identify the muscles described in Column A by choosing a response from Column B. Enter the correct letter in the answer blank. Select a different color for each muscle description provided with a color-coding circle, and use it to color the coding circles and corresponding muscles on Figure 6-9. Complete the illustration by labeling those muscles provided with leader lines. *- pg 119*

Column A

- _____ 1. Hip flexor, deep in pelvis; a composite of two muscles
- _____ 2. Used to extend the hip when climbing stairs
- _____ 3. "Toe dancer's" muscle; a two-bellied muscle of the calf
- _____ 4. Inverts and dorsiflexes the foot
- _____ 5. Muscle group that allows you to draw your legs to the midline of your body, as when standing at attention
- _____ 6. Muscle group that extends the knee
- _____ 7. Muscle group that extends the thigh and flexes the knee
- _____ 8. Smaller hip muscle commonly used as an injection site
- _____ 9. Muscle group of the lateral leg; plantar flex and evert the foot
- _____ 10. Straplike muscle that is a weak thigh flexor; the "tailor's muscle"
- _____ 11. Like the two-bellied muscle that lies over it, this muscle is a plantar flexor

Column B

- A. Adductors
- B. Biceps femoris
- C. Fibularis muscles
- D. Gastrocnemius
- E. Gluteus maximus
- F. Gluteus medius
- G. Hamstrings
- H. Iliopsoas
- I. Quadriceps
- J. Rectus femoris
- K. Sartorius
- L. Semimembranosus
- M. Semitendinosus
- N. Soleus
- O. Tibialis anterior
- P. Vastus intermedius
- Q. Vastus lateralis
- R. Vastus medialis

General Body Muscle Review

23. Complete the following statements describing muscles. Insert the correct answers in the answer blanks.

- _____ 1. Three muscles— (1), (2), and (3) —are commonly used for intramuscular injections in adults.
- _____ 2. _____ 3. The insertion tendon of the (4) group contains a large sesamoid bone, the patella.
- _____ 4. The triceps surae insert in common into the (5) tendon.
- _____ 5. The bulk of the tissue of a muscle tends to lie (6) to the part of the body it causes to move.
- _____ 6. The extrinsic muscles of the hand originate on the (7).
- _____ 7. _____ 8. Most flexor muscles are located on the (8) aspect of the body; most extensors are located (9). An exception to this generalization is the extensor-flexor musculature of the (10).
- _____ 9. _____ 10. The pectoralis major and deltoid muscles act synergistically to (11) the arm.
- _____ 11.

24. Circle the term that does not belong in each of the following groupings.

- | | | | | |
|---------------------|------------------|--------------------|----------------------|------------|
| 1. Vastus lateralis | Vastus medialis | Knee extension | Biceps femoris | |
| 2. Latissimus dorsi | Pectoralis major | Shoulder adduction | Antagonists | |
| 3. Buccinator | Frontalis | Masseter | Mastication | Temporalis |
| 4. Vastus medialis | Rectus femoris | Iliacus | Origin on coxal bone | |

25. Identify the numbered muscles in Figure 6-11 by placing the numbers in the blanks next to the following muscle names. Then select a different color for each muscle provided with a color-coding circle and color the coding circle and corresponding muscle in Figure 6-11.

pg 123

- _____ 1. Orbicularis oris
- _____ 2. Pectoralis major
- _____ 3. External oblique
- _____ 4. Sternocleidomastoid
- _____ 5. Biceps brachii
- _____ 6. Deltoid
- _____ 7. Vastus lateralis
- _____ 8. Frontalis
- _____ 9. Rectus femoris
- _____ 10. Sartorius
- _____ 11. Gracilis
- _____ 12. Adductor group
- _____ 13. Fibularis longus
- _____ 14. Temporalis
- _____ 15. Orbicularis oculi
- _____ 16. Zygomaticus
- _____ 17. Masseter
- _____ 18. Vastus medialis
- _____ 19. Tibialis anterior
- _____ 20. Transversus abdominis
- _____ 21. Rectus abdominis

26. Identify each of the numbered muscles in Figure 6-12 by placing the numbers in the blanks next to the following muscle names. Then select different colors for each muscle and color the coding circles and corresponding muscles on Figure 6-12. *- pg 125*

- _____ 1. Adductor muscle
- _____ 2. Gluteus maximus
- _____ 3. Gastrocnemius
- _____ 4. Latissimus dorsi
- _____ 5. Deltoid
- _____ 6. Semitendinosus
- _____ 7. Soleus
- _____ 8. Biceps femoris
- _____ 9. Triceps brachii
- _____ 10. External oblique
- _____ 11. Gluteus medius
- _____ 12. Trapezius

 THE FINALE: MULTIPLE CHOICE

36. Select the best answer or answers from the choices given.

1. Select the type(s) of muscle tissue that fit the following description: self-excitabile, pacemaker cells, gap junctions, limited sarcoplasmic reticulum.
 - A. Skeletal muscle
 - B. Cardiac muscle
 - C. Smooth muscle
 - D. Involuntary muscle
2. Skeletal muscle is *not* involved in:
 - A. movement of skin
 - B. propulsion of a substance through a body tube
 - C. heat production
 - D. inhibition of body movement
3. Which of the following are part of a thin myofilament?
 - A. ATP-binding site
 - B. Regulatory proteins
 - C. Globular actin
 - D. Calcium
4. Detachment of the cross bridges is directly triggered by:
 - A. hydrolysis of ATP
 - B. repolarization of the T tubules
 - C. the power stroke
 - D. attachment of ATP to myosin heads
5. Transmission of the stimulus at the neuromuscular junction involves:
 - A. synaptic vesicles
 - B. sarcolemma
 - C. ACh
 - D. axon terminal
6. Your ability to lift that heavy couch would be increased by which type of exercise?
 - A. Aerobic
 - B. Endurance
 - C. Resistance
 - D. Swimming
7. Which of the following activities depends most on anaerobic metabolism?
 - A. Jogging
 - B. Swimming a race
 - C. Sprinting
 - D. Running a marathon
8. The first energy source used to regenerate ATP when muscles are extremely active is:
 - A. fatty acids
 - B. glucose
 - C. creatine phosphate
 - D. pyruvic acid
9. Head muscles that insert on a bone include the:
 - A. zygomaticus
 - B. masseter
 - C. buccinator
 - D. temporalis
10. Lateral flexion of the torso involves:
 - A. erector spinae
 - B. rectus abdominis
 - C. quadratus lumborum
 - D. external oblique
11. Muscles attached to the vertebral column include:
 - A. quadratus lumborum
 - B. external oblique
 - C. diaphragm
 - D. latissimus dorsi
12. Muscles that help stabilize the scapula and shoulder joint include:
 - A. triceps brachii
 - B. biceps brachii
 - C. trapezius
 - D. rhomboids

13. Which of these thigh muscles causes movement at the hip joint?
 - A. Rectus femoris
 - B. Biceps femoris
 - C. Vastus lateralis
 - D. Semitendinosus
14. Leg muscles that can cause movement at the knee joint include:
 - A. tibialis anterior
 - B. fibularis longus
 - C. gastrocnemius
 - D. soleus
15. The main muscles used when doing chin-ups are:
 - A. triceps brachii and pectoralis major
 - B. infraspinatus and biceps brachii
 - C. serratus anterior and external oblique
 - D. latissimus dorsi and brachialis
16. The major muscles used in doing push-ups are:
 - A. biceps brachii and brachialis
 - B. supraspinatus and subscapularis
 - C. coracobrachialis and latissimus dorsi
 - D. triceps brachii and pectoralis major
17. Arm and leg muscles are arranged in antagonistic pairs. How does this affect their functioning?
 - A. It provides a backup if one of the muscles is injured.
 - B. One muscle of the pair pushes while the other pulls.
 - C. A single neuron controls both of them.
 - D. It allows the muscles to produce opposing movements.
18. Muscle A and muscle B are the same size, but muscle A is capable of much finer control than muscle B. Which of the following is likely to be true of muscle A?
 - A. It is controlled by more neurons than muscle B.
 - B. It contains fewer motor units than muscle B.
 - C. It is controlled by fewer neurons than muscle B.
 - D. Each of its motor units consists of more cells than the motor units of muscle B.

for #18

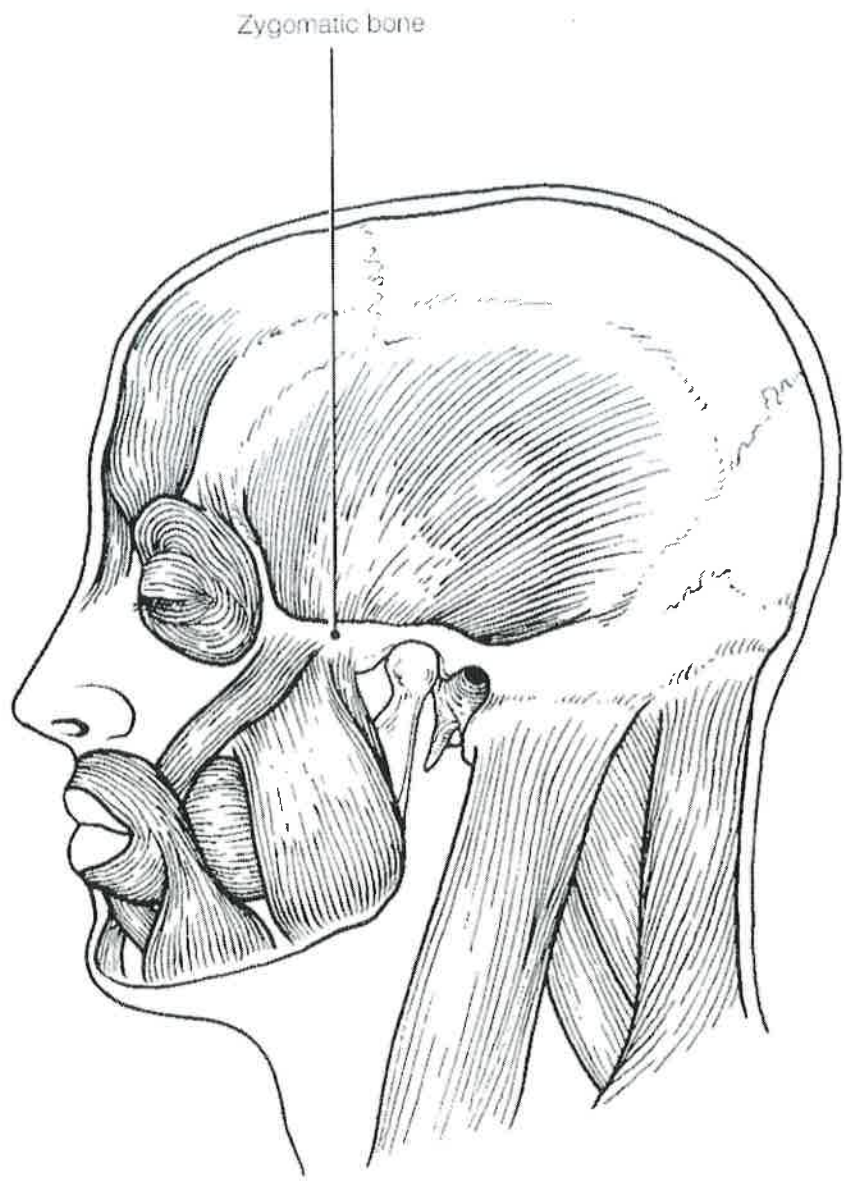


Figure 6-6

for # 19

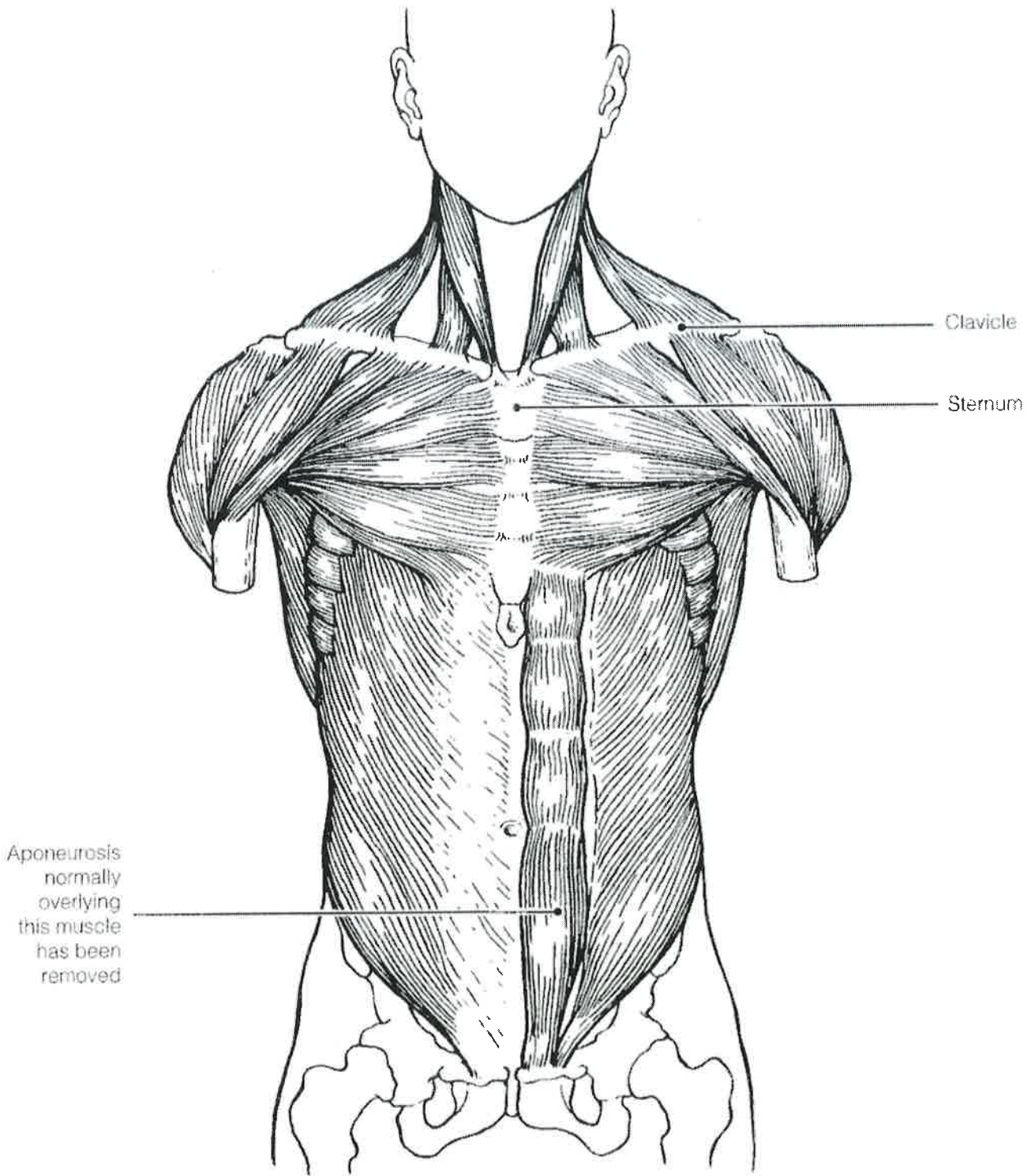


Figure 6-7

For # 20

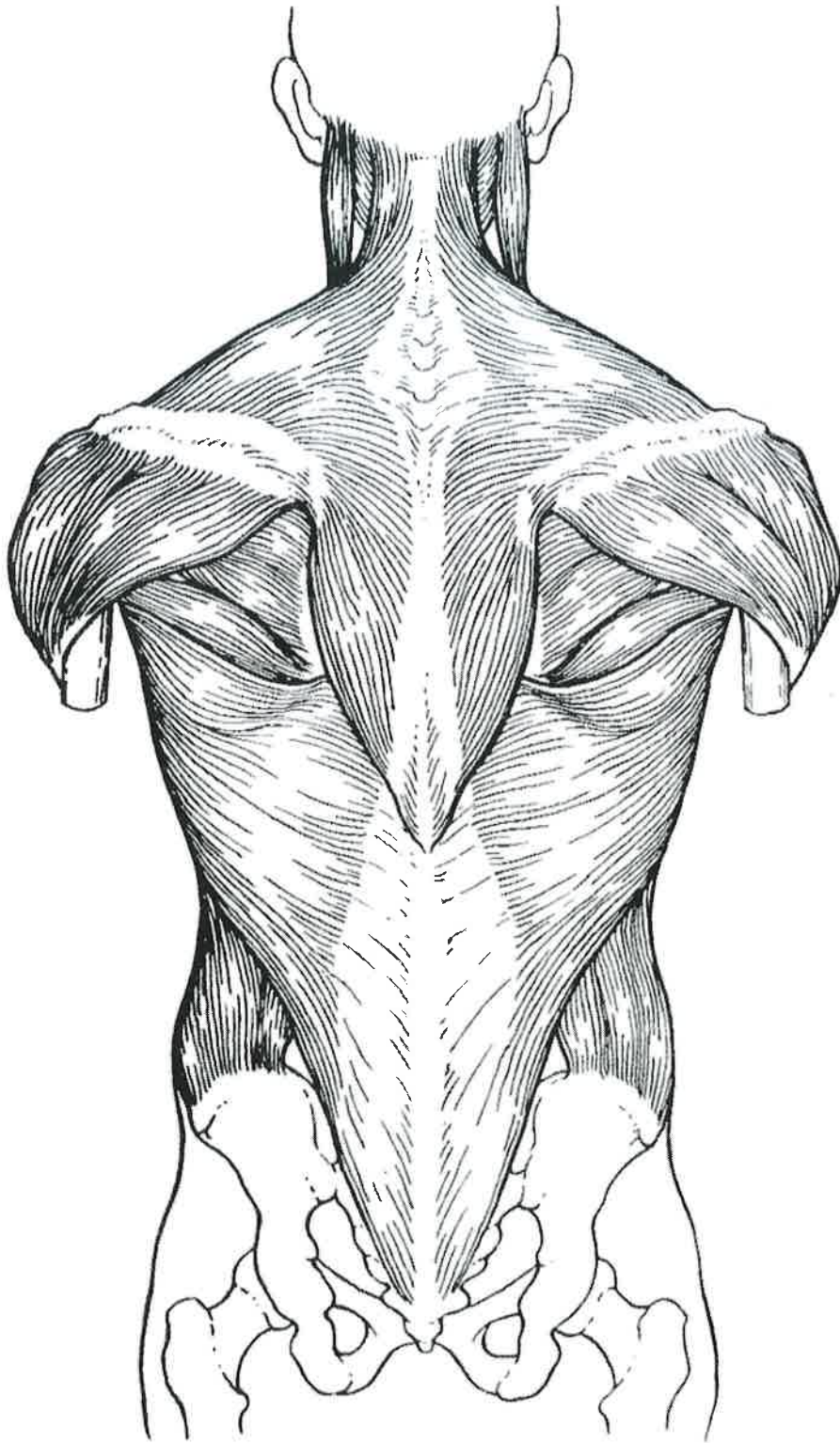


Figure 6-8

for #21

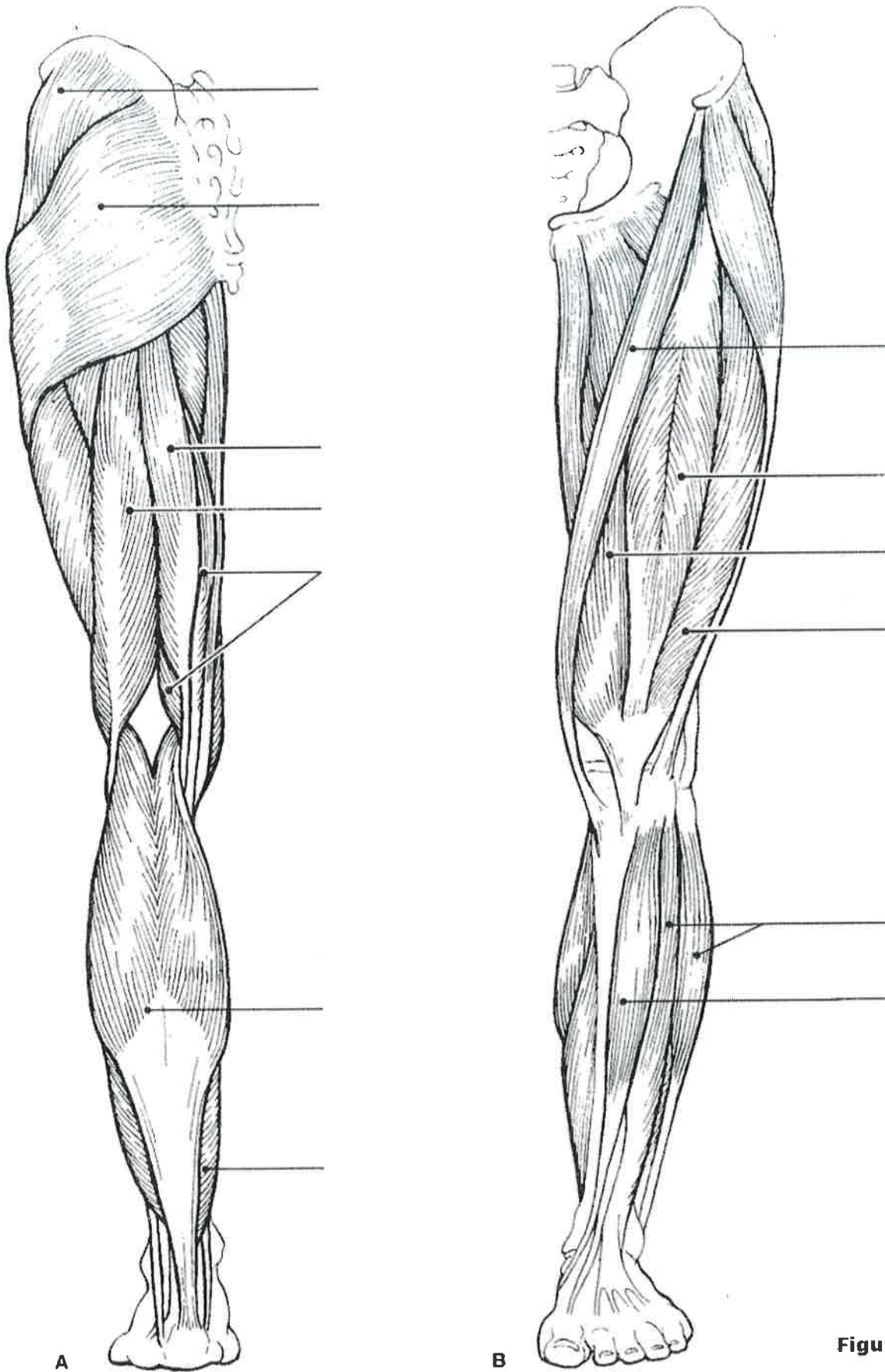


Figure 6-9

Muscles of the Arm and Forearm

22. Identify the muscles described in Column A by choosing a response from Column B. Enter the correct letter in the answer blank. Then select different colors for each muscle description provided with a color-coding circle and use them to color in the coding circles and corresponding muscles on Figure 6–10.

Column A

- _____ 1. Wrist flexor that follows the ulna
- _____ 2. Muscle that extends the fingers
- _____ 3. Muscle that flexes the fingers
- _____ 4. Muscle that allows you to bend (flex) the elbow
- _____ 5. Muscle that extends the elbow
- _____ 6. Powerful shoulder abductor, used to raise the arm overhead

Column B

- A. Biceps brachii
- B. Deltoid
- C. Extensor carpi radialis
- D. Extensor digitorum
- E. Flexor carpi ulnaris
- F. Flexor digitorum superficialis
- G. Triceps brachii

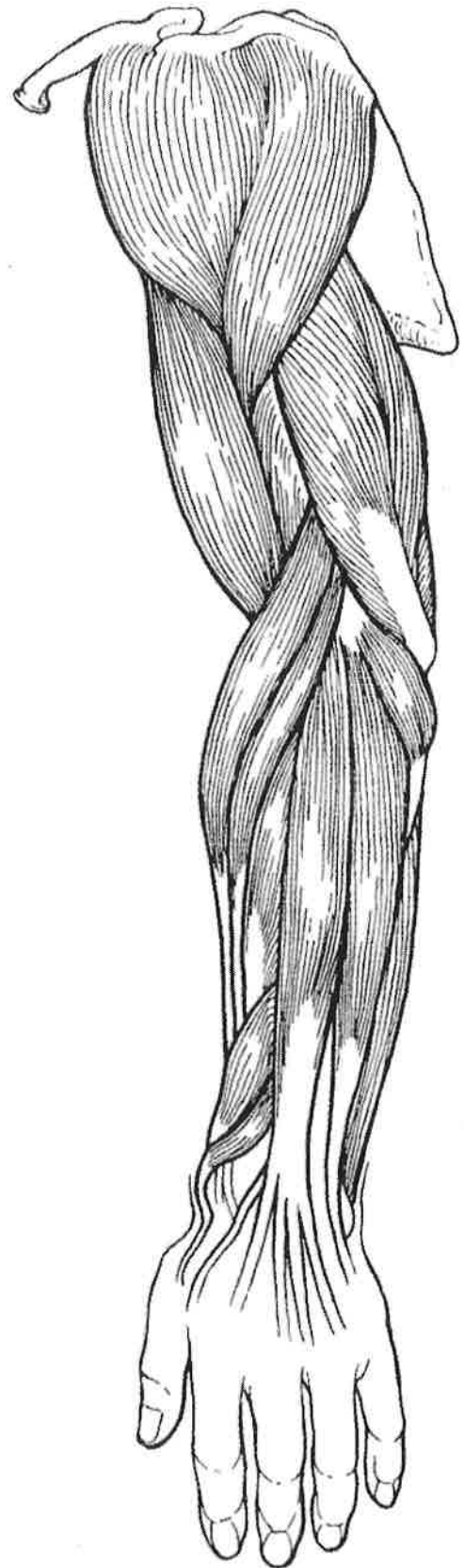

Figure 6–10

For # 25

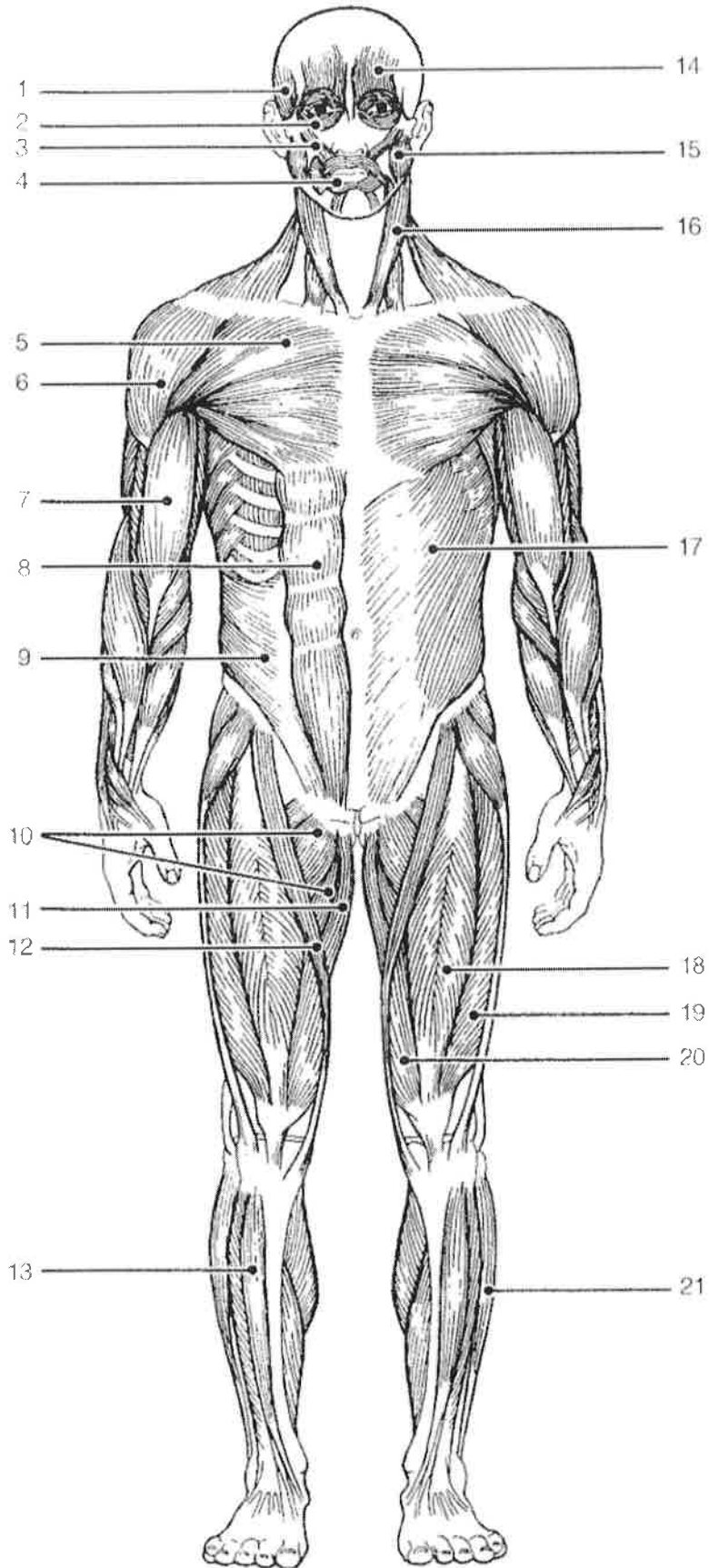


Figure 6-11

For # 26

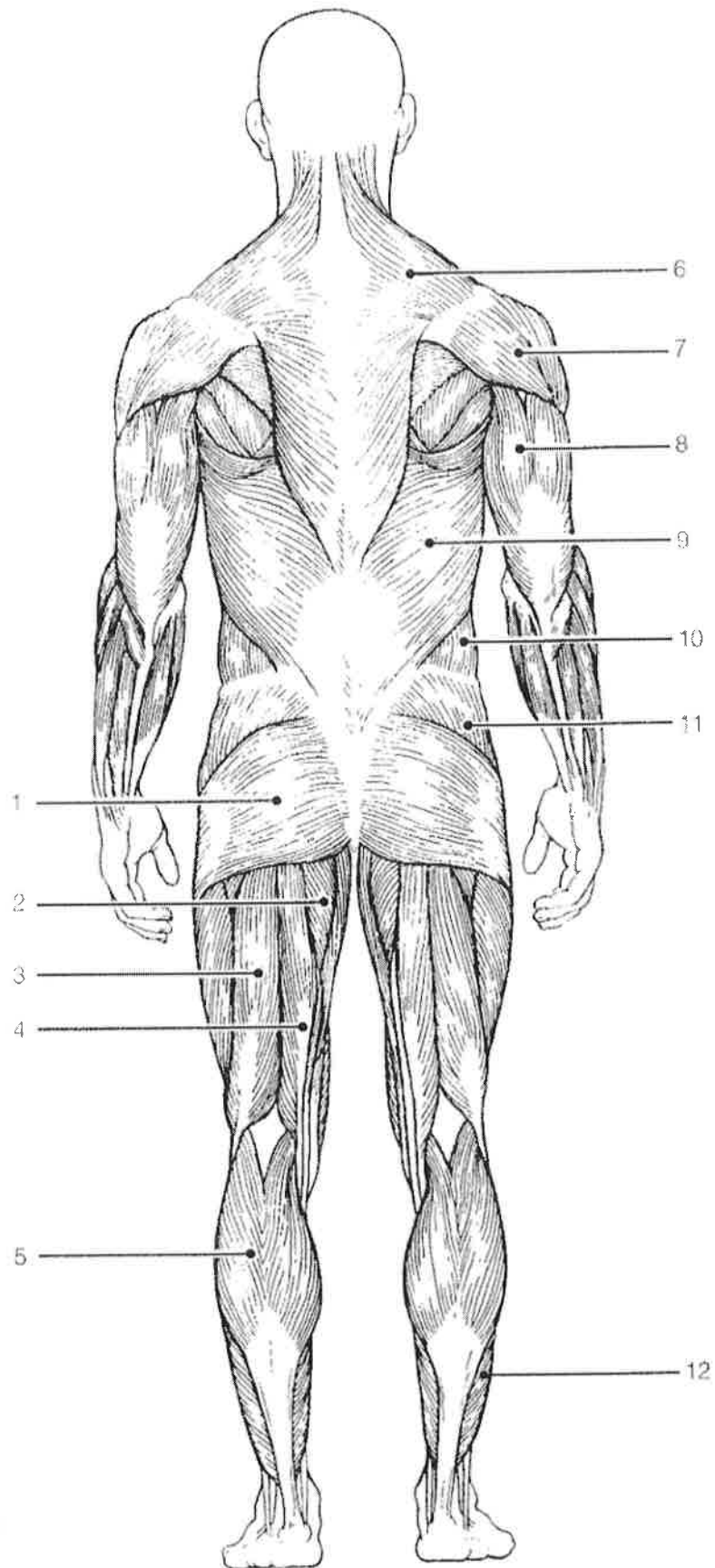


Figure 6-12